

## Coding for Nerve Procedures

**Coding on the River**  
**Jacksonville, FL**  
**18 Sept 2010**



Peter M. Murray, MD  
 Professor of Orthopedic Surgery  
 Director for Education  
 Mayo Clinic  
 Jacksonville, FL

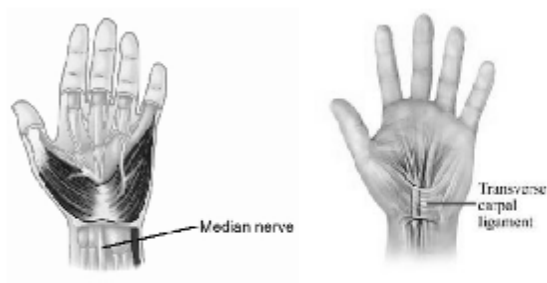
## Nerve Compression

- Carpal Tunnel Syndrome
- Cubital Tunnel Syndrome

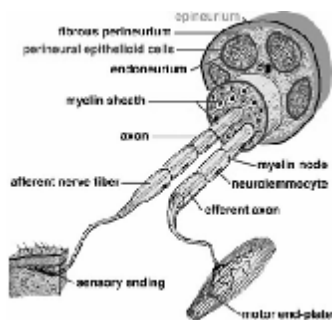
## Nerve Procedures

- Nerve decompression
- Nerve repair
- Nerve reconstruction
  - Nerve grafting
  - Nerve transfers
- Tendon transfers

## Carpal Tunnel Syndrome

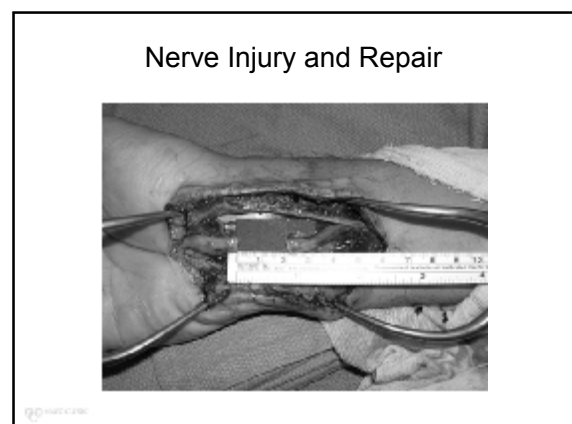
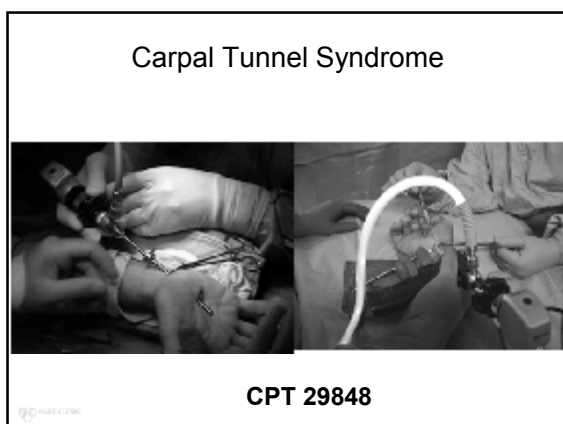
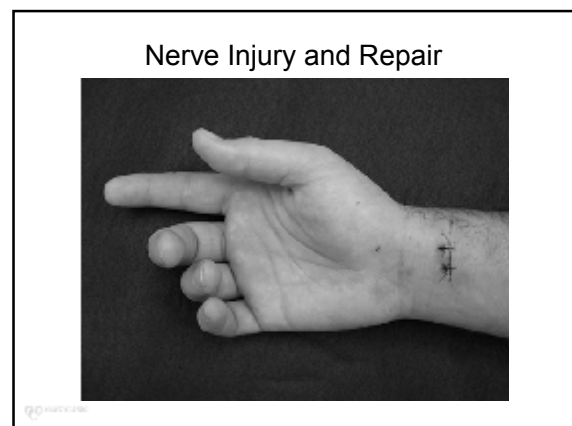
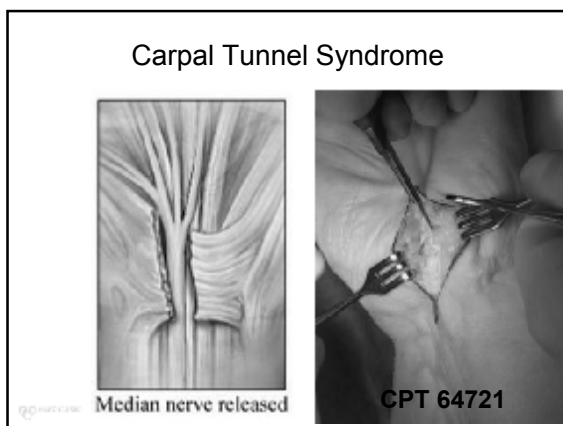
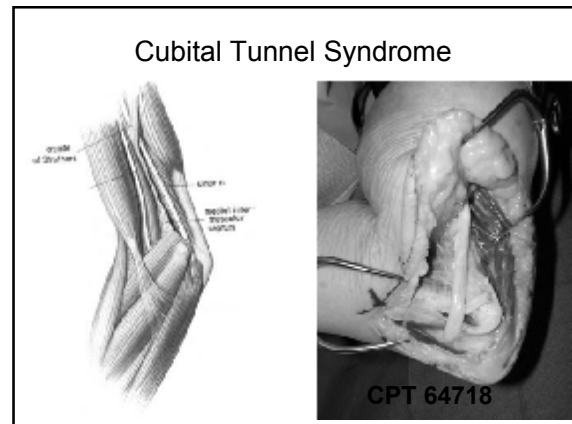
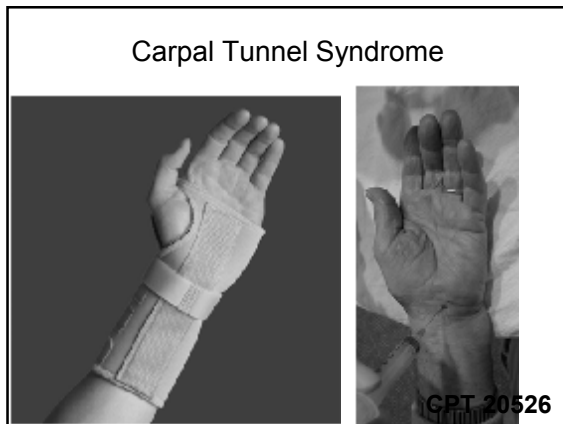


## Nerve Anatomy and Function

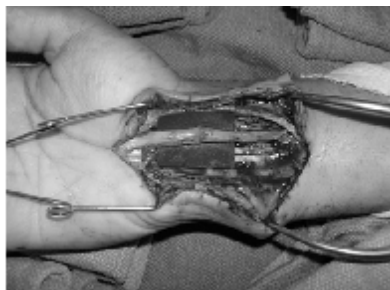

## Carpal Tunnel Release

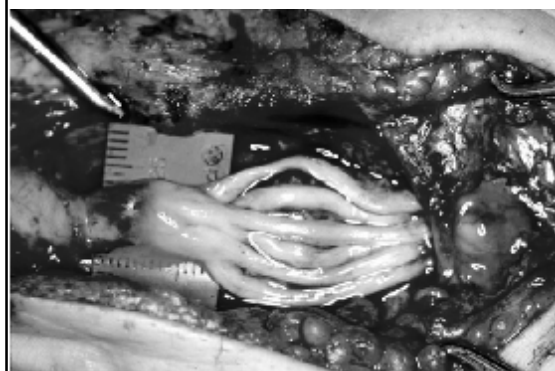



## Nerve Injury and Repair




CPT 64856




CPT 64897

## Nerve Reconstruction

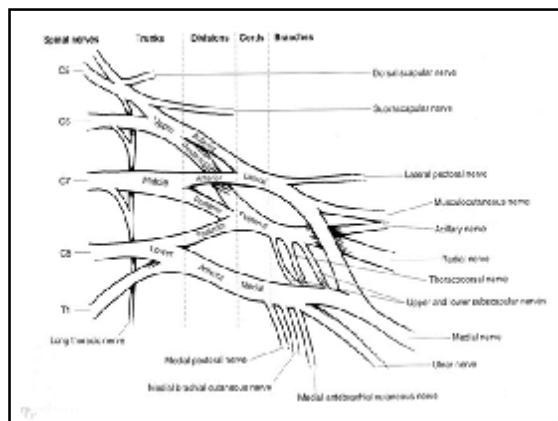
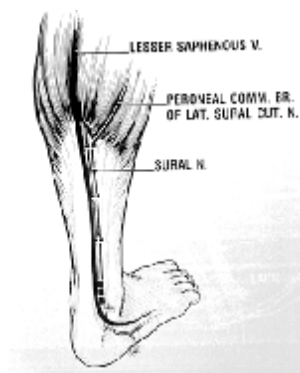



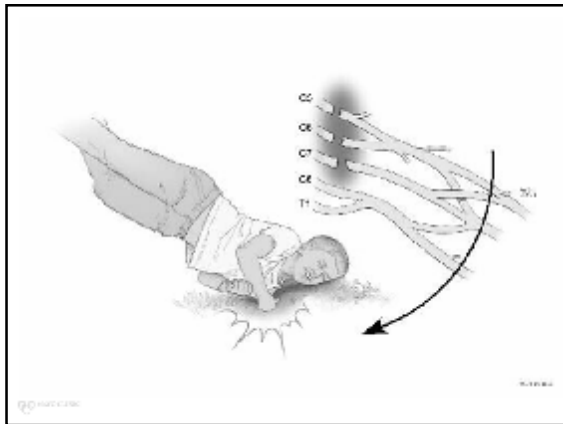
## Nerve Transfer

- Transfer of a functioning peripheral nerve to a non-functioning peripheral nerve for the purpose of restoring muscle function.

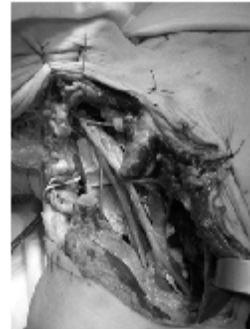


## Sural Nerve





### Brachial Plexus Exploration



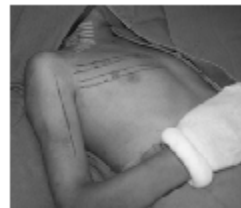CPT 64713

### Brachial Plexus Injuries

- 90% of patients are young males
- 75% associated with head injury, thoracic trauma or c-spine injury
- 20% associated with UE vascular trauma
- 1% of MVAs and 4% of MCAs

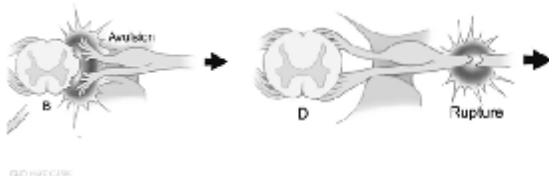
HARVEY

### Intercostal Nerve Transfer

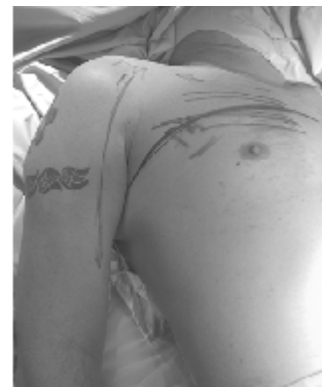


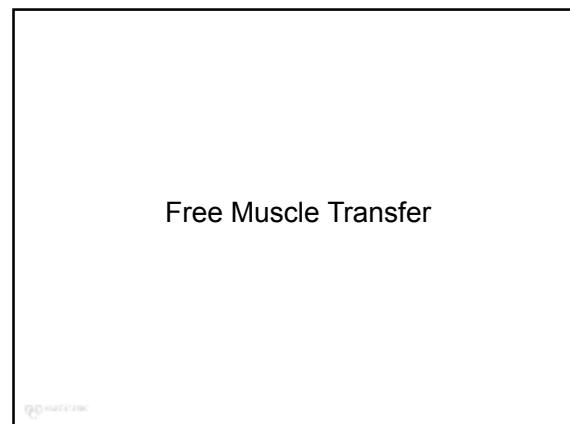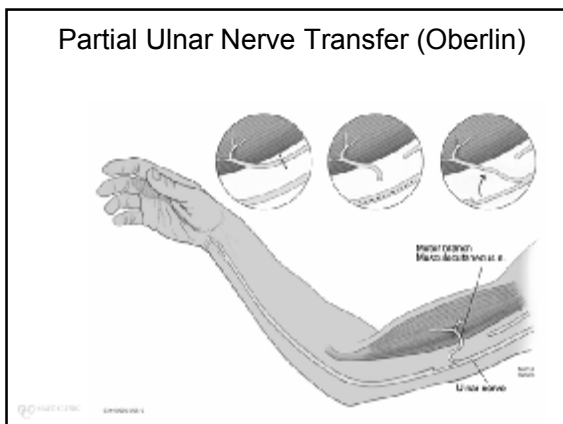
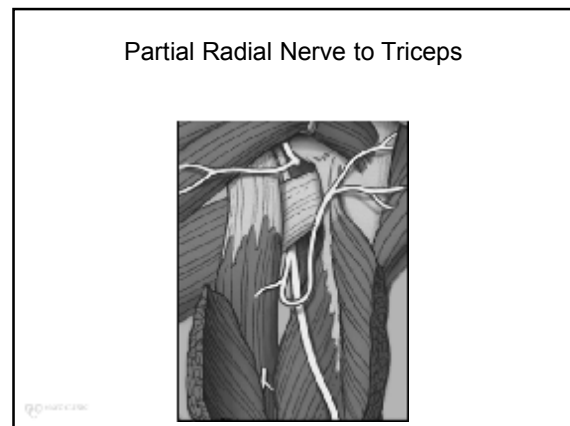
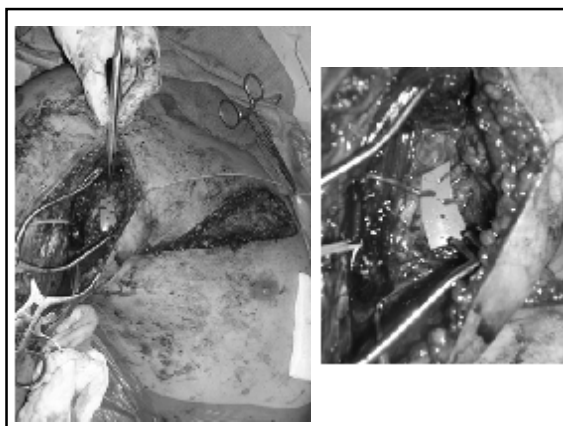
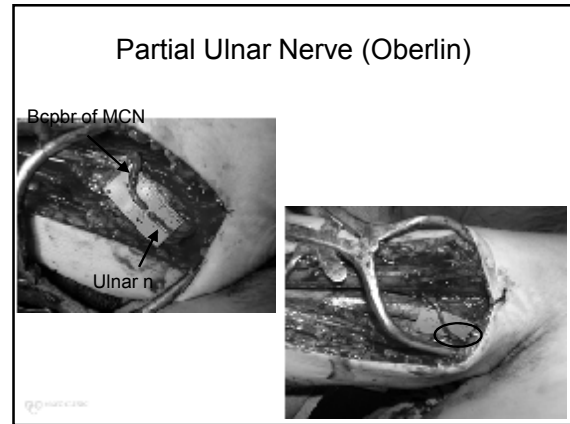
### Brachial Plexus Injuries

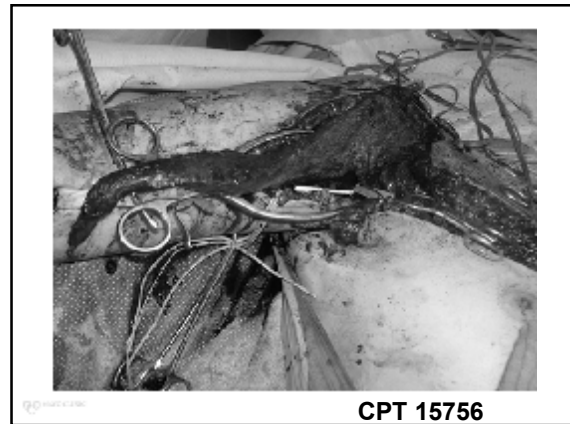
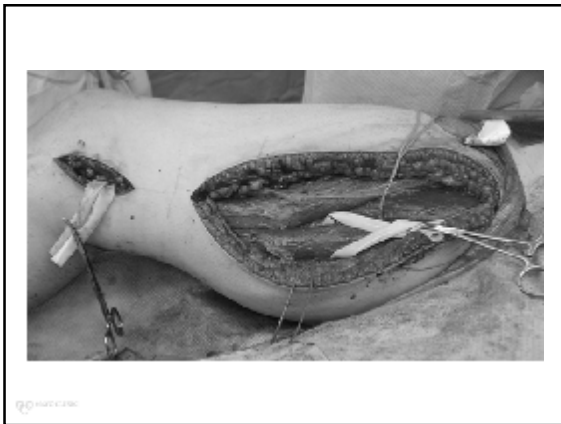- Surgery indicated when there is complete nerve disruption (neurotmesis)
  - nerve root avulsion from spinal cord
  - Peripheral nerve rupture



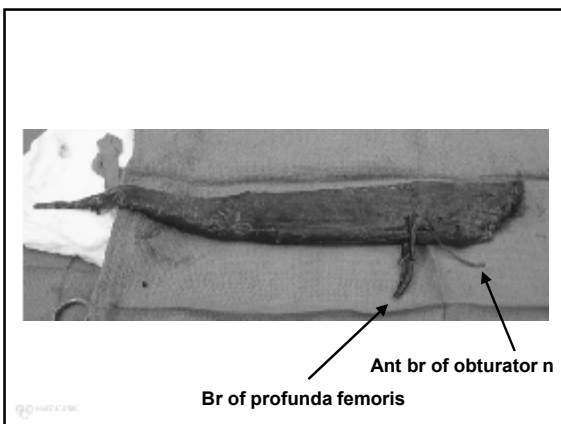
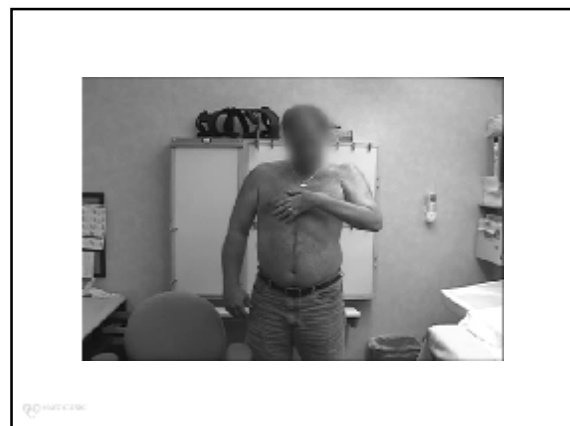
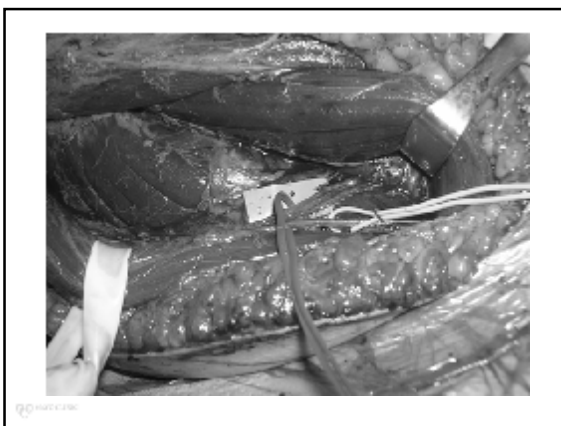HARVEY







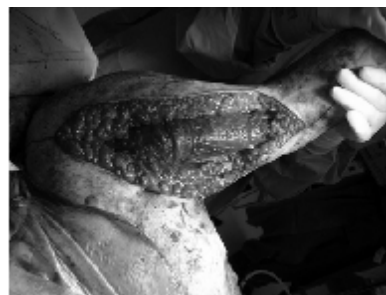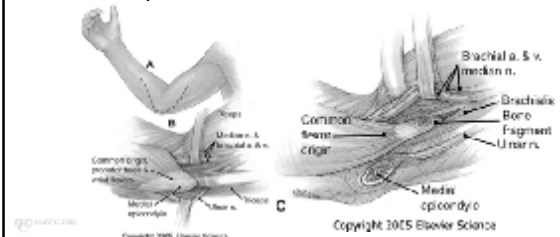
CPT 15756



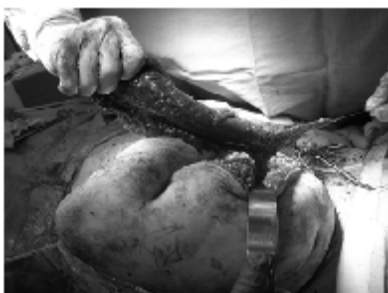## Tendon Transfers

### Steindler Flexorplasty (CPT 24330)

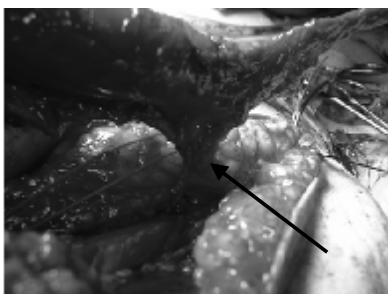
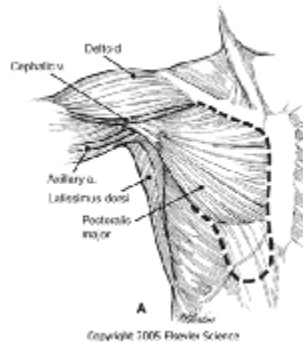
- Arthur Steindler 1918
- Flexor-pronator muscle advancement



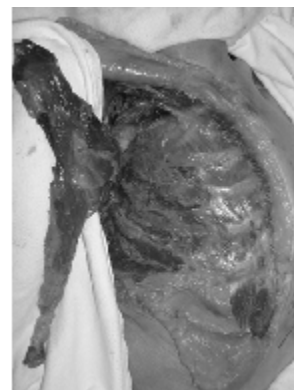
### Latissimus Dorsi Tendon Transfer (CPT24320)



### Pectoralis Major Tendon Transfer

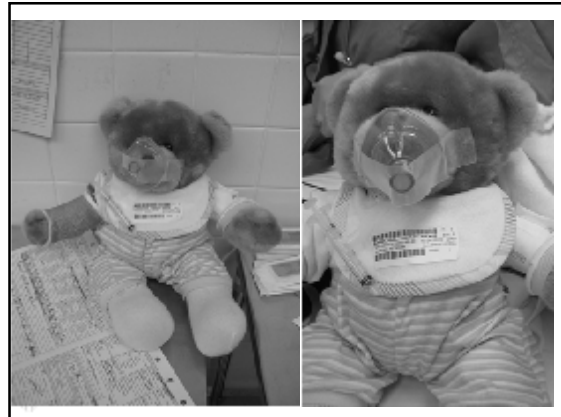

Thoracodorsal artery and nerve

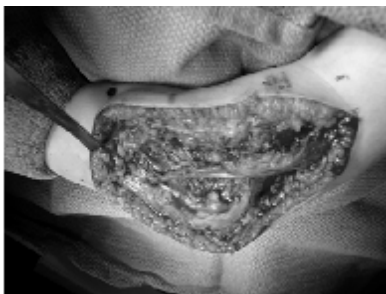


### Triceps to Biceps Transfer

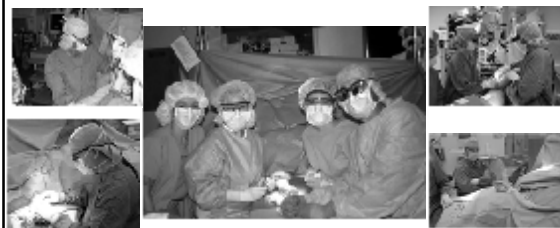- Arthrogryposis
  - Non-progressive joint contractures present at birth
  - Non-functioning muscles
  - Cause unknown



*"To Those Who Have Nothing a Little is a Lot"*  
Sterling Bunnell, MD



*Thank You*



Hand and Microvascular Surgery Service  
Mayo Clinic  
Jacksonville, FL